

Immediate Total Tooth Replacement

David A. Garber, DMD
Professor
Department of Periodontics

Clinical Professor
Departments of Oral
Rehabilitation and
Periodontics
Medical College of Georgia
School of Dentistry
Augusta, Georgia

Clinical Professor
Department of Prosthodontics
Louisiana State University
New Orleans, Louisiana

Adjunct Professor
Department of Restorative
Dentistry
University of Texas
San Antonio, Texas

Private Practice
Atlanta, Georgia

**Maurice A. Salama,
DMD**
Clinical Assistant Professor of
Periodontics
University of Pennsylvania
Philadelphia, Pennsylvania

Clinical Assistant Professor of
Periodontics
Medical College of Georgia
Augusta, Georgia

Visiting Professor of
Periodontics
Nova University in Florida
Fort Lauderdale, Florida

Private Practice
Atlanta, Georgia

Henry Salama, DMD
Assistant Clinical Professor
Department of
Periodontology
University of Pennsylvania
Philadelphia, Pennsylvania

Private Practice
Atlanta, Georgia

The recent potential for extracting a compromised tooth and immediately replacing it with an implant supporting a provisional restoration has brought implant dentistry into the general dentist's realm of treatment planning.¹⁻⁵ The potential for the immediate implant loading is already well documented in the literature for the mandible. More recently, immediate loading using cross-arch stabilized prostheses on several implants has been documented for the maxilla. It is apparent that the cross-arch stabilization of several implants prevents any micro-movement of the fixtures during the initial healing phase, which allows direct bone apposition and osseointegration as opposed to the development of a fibrous encapsulation of the implant. This approach represented a distinct deviation from the original Brånemark protocol of staged implant placement and delayed loading to one-stage implant placement with immediate loading.

The key to successful maxillary one-stage immediate implant loading is to prognostically evaluate the tooth in question and ensure that it is only the tooth that is compromised and not the soft tissue or osseous form of the surrounding attachment apparatus. The evaluation of the

soft-tissue profile of the restorative recipient site should be considered from three distinct aspects: the mesial and distal interproximal papillae on each side of the tooth in question and the relative arcuate form of the facial free gingival margin. These three aspects should be assessed not only for inflammation but also for replicating the form on the adjacent teeth.

The underlying supporting osseous scaffold is essential to the maintenance of the soft-tissue profile and is evaluated using a periodontal probe under anesthesia. Generally, the crest of the interproximal bone should not exceed a distance of 4.5 mm^{6,7} from the contact point of the proposed restoration to the osseous or at least one of the supporting elements (teeth or implants) on either side of the papilla (Table 1). The osseous, which is on the direct labial aspect of the tooth slated for extraction, should exhibit no dehiscence or fenestration and the crest should be within 3 mm of the free gingival margin.

Another element essential to the esthetic success of tooth replacement is the atraumatic removal of the compromised tooth without any untoward damage to the attachment apparatus. The compromised tooth should be deemed nonsalvageable as a result of endodontic failure, frac-

Abstract: *Successful implant placement at the time of extraction has been documented. Implant placement at the time of extraction was initially performed as a two-stage procedure often with barrier membranes and sophisticated second-stage surgical uncoverings. The authors describe the next generation of this technique, including atraumatic tooth removal with simultaneous root form, implant placement, and temporization at one appointment. This technique of "Immediate Total Tooth Replacement" allows for the maintenance of the bony housing and soft-tissue form that existed before extraction, while at the same time establishing a root form anchor in the bone for an esthetic restoration.*

Table 1—Parameters for Predictable Papillae*

Class	Restorative Environment	Proximity Limitations	Vertical Soft-Tissue Limitations	
			Mean	Range
1	Tooth-Tooth	1	4.5 to 5 mm	
2	Tooth-Pontic	N/A	6.75	4 to 9 mm
3	Pontic-Pontic	N/A	6.5	5 to 9 mm
4	Tooth-Implant	1.5 mm	6.5	4 to 9 mm
5	Implant-Pontic	N/A	5.75	5 to 9 mm
6	Implant-Implant	3 mm	4.5	4 to 7 mm

*Cumulative data of two test groups: (A) 37 patients with single and multiple implants in the maxillary anterior region, and (B) 11 patients who received conventional anterior fixed bridgework with pontics. Vertical soft-tissue depth was measured interproximally immediately adjacent to the implants, pontics, and teeth (Salama H, Garber DA, Salama MA, Presented at the Academy of Periodontology Annual Meeting, Hawaii 2000, General Session).

Table 2—Immediate Total Tooth Replacement

	Anterior	Posterior
Total Implants Placed	39	16
Failures	3	2

ture, extensive root caries, or external root resorption as opposed to periodontal breakdown. In these types of clinical scenarios, the surrounding attachment apparatus is invariably not compromised, which provides an opportunity for optimal extraction. An optimal extraction situation provides the potential for immediate implant placement and often for immediate placement of the provisional restoration to replace the missing tooth (ie, immediate total tooth replacement).

Clinical Study

A clinical pilot study was initiated by the authors in February 1998 to develop the concept of immediate total replacement of single teeth. Essentially, if the stability and integrity of the titanium/bone interface can be protected from micromovement during the early healing phase, osseointegration should remain predictable despite the presence of a temporary restoration^{8,9} (Table 2). This study consists of 39 optimal type 1 extraction sites with intact osteotomies and incisionless fixture placement using 40 Ncm of torque. The immediate fixed interim prosthesis had no occlusal contact in centric or excursive mandibular movement. The study has run for 34 months with 3 total

failures: 2 mandibular right first molars and 1 maxillary left canine. A 50% failure rate has been recorded in molars, which is not an optimal site for the technique (Salama H, Garber DA, Salama MA, Presented at the Academy of Periodontology Annual Meeting, Hawaii 2000, General Session).

Immediate Implant Placement

Immediate placement of the implant with a temporary restoration requires a change from the traditional cylindrical implant protocol in the following aspects to ensure primary stability without micromovement during the initial healing and osseointegration phase.

Macrogeometrical Implant Form—The diameter of the fixture head needs to be matched to the mesiodistal width of the coronal aspect of the socket. This will negate the need for a membrane to facilitate guided bone regeneration in the critical gap that normally occurs as a result of the disparity in diameter of cylindrical implants and the top of the socket. This helps to avoid many complications, including soft-tissue recession that often occurs around exposed membranes.

An implant design that decreases in diameter from the coronal to the apical end, such as FRIALIT[®]-2^a, Paragon[™] Tapered Swiss Plus^b, or the Steri-Oss[®] Replace^c, becomes essential to prevent compromising the thin labial plate of a socket by perforation or overstressing. The naturally occurring bone concavity in the anterior maxilla is also avoided by such a design. A screw-type fixture is preferable to provide the initial mechanical fixation/stability of the titanium implant within the underlying osseous form. The screw threads should be designed to be mechanically active only in the apical two-thirds of the implant where the bone is thicker and less likely to be compromised by the self-cutting threads. In the coronal portion of the implant site, noncutting threads that will not tear through the thin cortical plate of the alveolar sockets are integral.

Microgeometrical Implant Surface—The microgeometry of the implant surface suggests that creating a roughened surface to the implant can accelerate the process of osseointegration, sec-

^aFriadent, Irvine, CA 92618

^bSulzer Dental, Encino, CA 91436

^cNobel BioCare USA, Yorba Linda, CA 92887

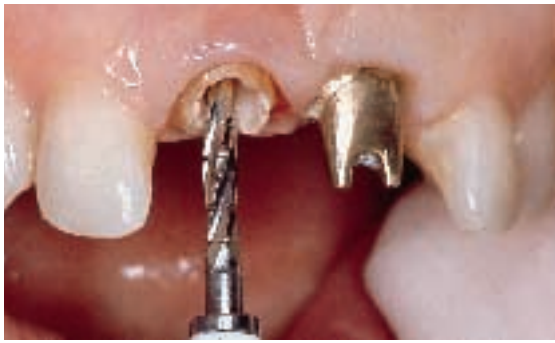

Figure 1—A 2-mm twist drill is inserted into the root canal after the gutta percha and extends through the apex into native bone.

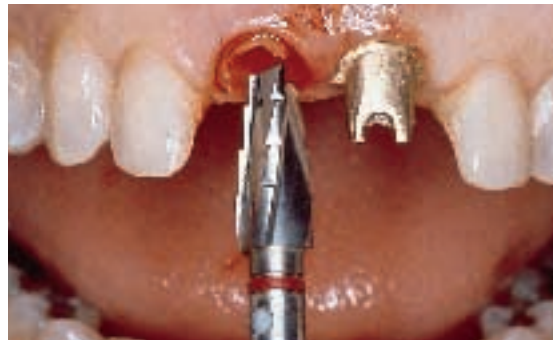

Figure 2—A stepped-tapered FRIALIT®-2 drill is used to remove the remaining root structure of the tapered root without compromising the bone.

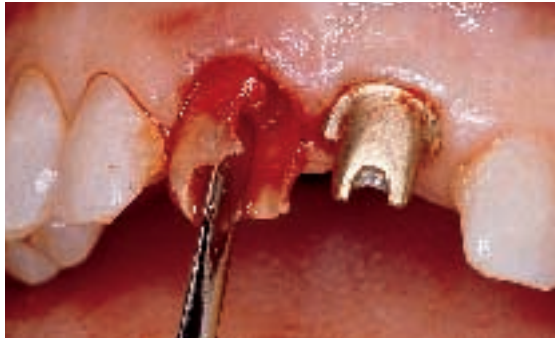

Figure 3—The remaining root fragment is removed using a Periostome to sever the periodontal ligament fibers by collapsing the root periphery inwards and lifting it out coronally.

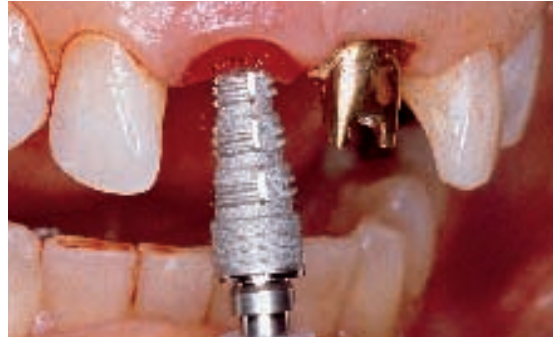

Figure 4—A stepped-tapered FRIALIT®-2 implant is inserted after coring out the resorping root in an incisionless mode.

ondary biologic stabilization, and the early percentage of bone-to-titanium contact. The original machined surface may be grit-blasted, acid-etched, or titanium-plasma-sprayed to achieve this roughened state as well as to increase the relative surface area. These microgeometric changes in the implant surface appear to result in an increased early bone-to-implant contact with resultant increased stability and decreased potential for a fibrous connective-tissue interface around the implant.

Extraction Technique—Tooth removal that does not compromise the extraction site can predict the success of immediate implant placement and nonloaded temporization. Various forms of atraumatic tooth removal are used depending on the specific clinical scenario. The Periostome[®] series of microextraction instruments is a useful instrument designed specifically for this purpose. The instruments are a cross between a miniscalpel and a tiny elevator that can be inserted into the periodontal ligament space to sever the fibers that run from the cementum to the surrounding osseous tissues. The instrument is worked back and forth in an oscillating motion moving toward the apex of

the root. When these fibers are severed, the root may be literally lifted out of the socket leaving the osseous of the alveolus unaffected. Additionally, the enveloping soft tissue has not been affected by an incision or iatrogenic trauma.

This technique is predicated on the presence of a periodontal ligament. When the periodontal ligament is absent (as in the case of external root resorption) an alternative approach is suggested. In these cases, when there is no differentiation between the periphery of the root and the surrounding osseous tissues (ie, no periodontal ligament space), traditional methods of tooth removal inevitably result in devastating osseous loss and soft-tissue compromise. In these situations, it is preferable to core out the root from the root canal peripherally. This technique¹⁰ is similar to that performed in routine restorative dentistry when fabricating a post-and-core in an existing root canal. Because the use of wide-diameter implants to obliterate the socket is essential to the success of this process, a tooth-form implant drill system should be selected that will not compromise the remaining labial plate of the alveolar socket and appropriately decreases in diameter aggressively toward the apex.

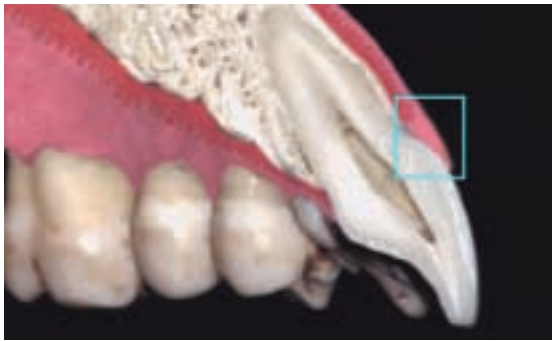

Figure 5—Computer-generated image of the extraction site showing the critical unsupported tissues of the restorative gingival interface.

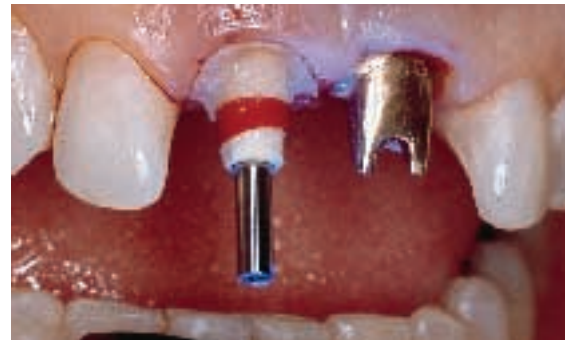


Figure 6—A temporary FRIALIT®-2 abutment is screwed down onto the implant and composite is introduced into the soft-tissue socket to support the restorative gingival interface.

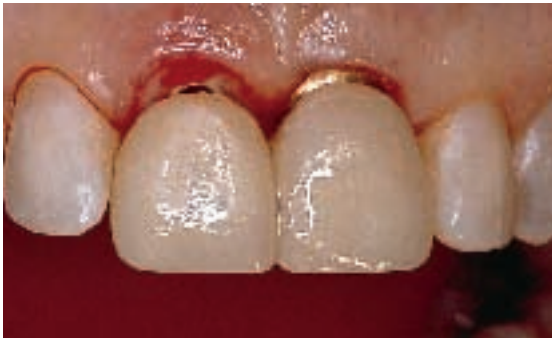

Figure 7—The emergence profile is restored as the temporary crown of the tooth is joined to the submergence profile on the temporary cylinder.

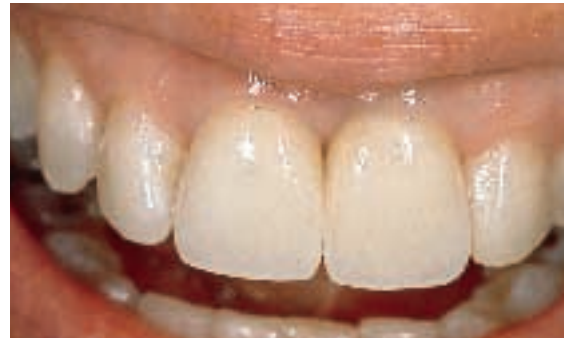

Figure 8—The finished all-ceramic restorations on metal abutments showing preservation of the soft-tissue form and completed at 8 weeks.

The nonsalvageable tooth is first cut off horizontally, level with the free gingival margin providing access to the underlying root canal. A 2-mm twist drill is inserted into the root canal, progressively removing the gutta percha entirely before extending through the apex into the surrounding native bone (Figure 1). This step is followed by a 3-mm twist drill, which is used to circumferentially remove more of the internal structure of the root. At this stage, changing to a tapering form of drill is crucial to protect the bone and a stepped-tapered drill that decreases in diameter apically is inserted into the root face (Figure 2). Depending on the size of the tooth, this may range in diameter from a 4.5-mm drill through to a 5.5-mm twist or even a 6.5-mm drill.

The drill is laterally directed toward that portion of the root circumferentially that shows the process of external root resorption. When this region is drilled out to reach bone, a Periosteal retractor can be inserted into the periodontal ligament space of the remaining root periphery, severing the periodontal ligament fibers, and allowing the root to be readily removed (Figure 3).

Implant Placement—After extraction, the site is prepared using the stepped-tapered drill in a size that corresponds to the mesial-distal dimension of the extracted tooth. This will prevent any encroachment on the interproximal bone that would compromise the papillae. During this drilling sequence, it is exceedingly useful to evaluate the amount of torque required to prepare the site. This evaluation will offer some indication to the potential primary mechanical stability of the fixture at the time of placement.

When the site is prepared, the implant is inserted (Figure 4) and torqued down using either hand or electronic instrumentation. During this phase, it is essential to quantify the amount of torque required¹¹ to drive the implant into place. Sophisticated electronic drilling units^c provide a readout of these torque levels. The anterior extraction site invariably provides for a distance beyond the apex of the root to increase the potential length of the implants, thereby enhancing the potential stability. In addition, the use of a tapered type of implant form that maximizes mechanical primary stability by engaging most of the lateral walls of the alveolus and

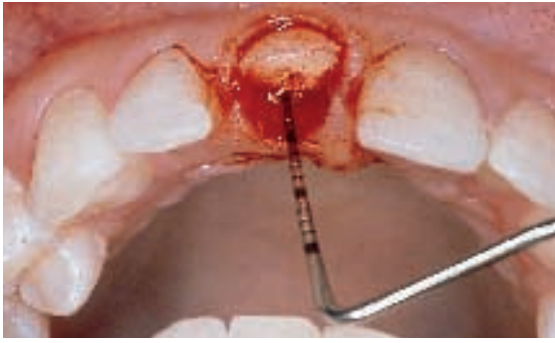


Figure 9—This patient presented with a deep lingual subosseous fracture of tooth No. 8 approximately 5 mm below the crest of the ridge. The tooth was deemed nonsalvageable.

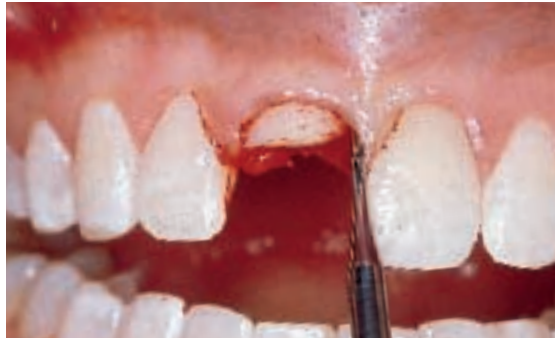

Figure 10—Atraumatic extraction technique using Periotome instrumentation into the periodontal ligament space.

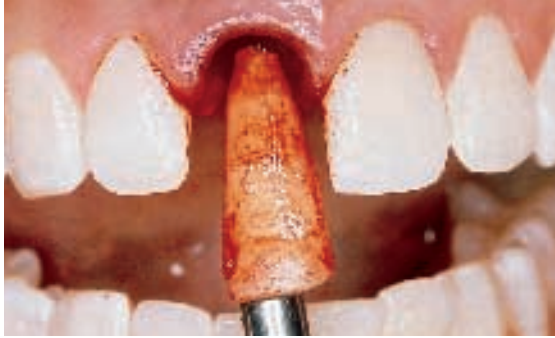

Figure 11—After full circumferential application of the Periotome, complete atraumatic extraction of the subosseous portion of the tooth root was successfully completed without any damage to the adjacent hard and soft tissues.



Figure 12—A step-tapered dedicated drill approximately 5.5 mm in diameter at the neck was then used to prepare the osteotomy for immediate implant placement. The design of the drill very closely resembles the shape and taper of the natural tooth.

the prepared site greatly enhances the potential success of this technique.

The wide diameter at the coronal portion of the implant is used to eliminate the need for a membrane by decreasing the critical gap at the root face. If this gap, created by the disparity in diameter between traditional cylindrical implants, is eliminated by the width of the fixture, the need for primary closure of the site to cover the membrane is also negated. This allows for a one-stage approach instead of the more complex two-stage approach. After drilling, the site is evaluated for perforation of the bone, particularly buccally, lingually, and apically. If a small perforation is encountered, it might be possible to use bone from the bone trap with or without the addition of a synthetic bone substitute and introduce it through this small perforation onto the labial surface, elevating the tissue without a flap.

Preservation of the Restorative Gingival Interface—When the implant is in position, the surrounding tissues of the restorative gingival interface need to be maintained. The esthetically crucial dimension of soft tissue

that extends from the free gingival margin coronally to the osseous crest apically for a distance of approximately 3 mm is supported entirely by the tooth or the implant-supported restoration (Figure 5). It is important to realize that this tissue is not supported by the osseous structure and that when the tooth has been removed, the original form of the tissue needs to be supported by some type of sculpted anatomic healing abutment or restoration to prevent the need for subsequent reconstructive periodontal procedures. The form of this tissue requires that gentle pressure be exerted laterally to support the full height of the papillae. In addition, the degree of subgingival support on the direct labial will affect the degree of curvature of the free gingival margin. The use of wide-diameter tooth-specific fixtures eliminates the need for deeper surgical placement (as is the case with standard implants) to develop the running room necessary for the traditional emergence form of an abutment.

The Submergence Profile—To preserve the form of the soft tissue, a waxing sleeve or temporary cylinder is screwed down into the

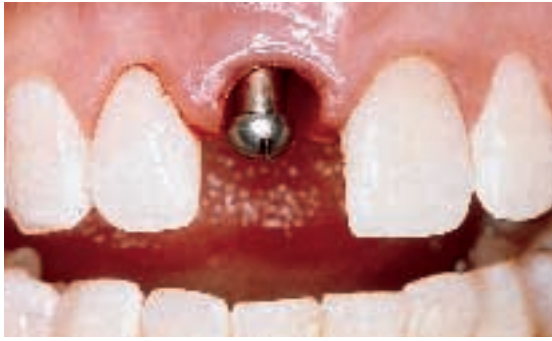

Figure 13—The implant carrier (showing through the extraction access) after immediate placement of a 5.5- X 13-mm stepped screw-type implant. When attempting to accomplish immediate total replacement procedures that involve immediate temporization, a threaded design is suggested rather than purely press fit.

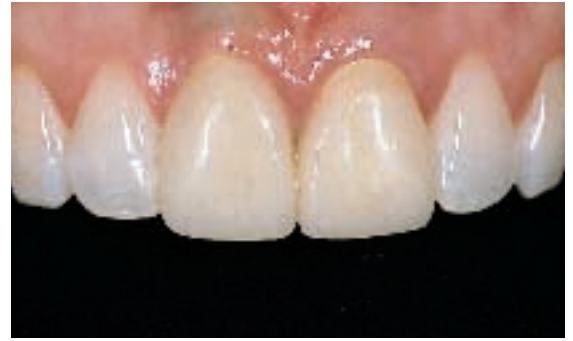

Figure 14—Immediate total replacement of tooth No. 8 with temporization in place at 1 week postoperative. This temporary restoration is nonfunctional and is purely used as an immediate esthetic replacement for the patient while maintaining the subgingival profile for the eventual final restoration.

implant face. Packable composite is introduced into the remainder of the surrounding soft-tissue socket to support the papillae laterally and the free gingival margin facially (Figure 6). When the soft-tissue form is once again identical to the original form, the composite material is light-cured. This step develops and then stabilizes the submergence profile for the “immediate total tooth replacement” technique.

The Emergence Profile—The portion of the restoration that emerges coronally from the free gingival margin to replace the crown form of the extracted tooth may be referred to as the *emergence profile*. This profile or tooth form may now be developed using acrylic or composite in a vacuform matrix or using a preformed tooth-colored polycarbonate shell (Figure 7). Access is provided for the retaining screw through a hole in the lingual aspect of the provisional restoration. When cured, the restoration is completed in the laboratory or chairside using acrylic burs and a clear resin, such as Palaseal[®],^d or SternVantage[™],^e. The restoration, which is now comprised of both the optimal submergence profile (to support the tissue) and the emergence profile (to replace the esthetics of the crown of the tooth), is screwed down into position. In this manner, an extracted tooth can readily be replaced to natural form at the same visit (Figure 8).

Occlusion—In maximum intercuspation and/or excursive movements of the mandible, contact with the restoration should be avoided. In this way, any forces directed toward the tooth will

inevitably be reduced by the interspersed bolus of force. Short of some parafunctional habit involving a hard object, the forces on the underlying healing implant should be relatively few, infrequent, and low in magnitude.

Requirements for Immediate Total Tooth Replacement

1. The osseous tissue and the soft tissue surrounding the compromised tooth should not be affected, and should provide native bone in the socket and beyond for primary stability.
2. The form of the soft tissues and the restorative gingival interface should be in harmony with the adjacent teeth and not compromised.
3. Primary stability of the implant should be a result of mechanical fixation. This stability is greatly enhanced by a screw-type wide-diameter implant that is also tapered to maximize use of the surrounding socket walls and the bone beyond the original root apex without perforating through the buccal plate.
4. Implant length should be at least 11 mm.
5. The implant should be torqued down to at least 40 Ncm of primary stability. Although a lesser torque force may similarly eliminate micromovement, no real research data is yet available defining this cut off point. The authors use this empirical data for their own regimen.
6. Microsurface topography should be roughened (ie, grit-blasted, acid-etched, or titanium-plasma-sprayed) to accelerate early healing, increase bone apposition, and biologic stability.

^dJF Jelenko & Co, Armonk, NY 10504

^eSterngold Restorative Systems, Attleboro, MA 02703

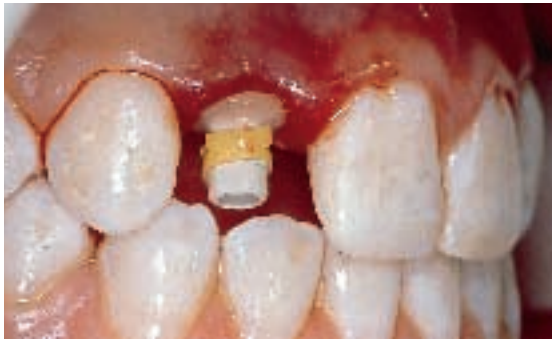

Figure 15—The lateral incisor is extracted using a Periotome. The implant is immediately inserted without raising a flap, and the temporary cylinder is positioned with composite placed in the soft-tissue socket to preserve the restorative gingival interface contour.

7. Soft-tissue form should be maintained using composite over a temporary cylinder in the submergence zone.

Conclusion

Initial studies have indicated that in specific types of clinical scenarios, where a nonsalvageable tooth (Figure 9) is surrounded by a noncompromised attachment apparatus, removal of this hopeless tooth and immediate total replacement by an implant and restoration is a viable option.¹⁻³ To optimize success of the procedure, the authors suggest wide-diameter tapered fixtures, which are essential to negate the need for a membrane by obliterating the access to the socket coronally while decreasing in diameter as it extends apically so as not to perforate through the labial plate. An incisionless approach (whereby a surgical flap is not raised) further enhances this technique by providing access to the underlying bone through the extraction socket and maintaining the periosteum intact (Figures 10 and 11). This approach preserves the esthetic integrity of the restorative gingival interface, while maintaining the crucial blood supply to the highly vulnerable labial plates by not stripping or elevating the periosteum containing the capillary plexus and arterioles.

The stability of the implant is mechanically optimized in the early phase by using a screw-type implant of maximum length and decreasing apical taper (Figures 12 and 13). Early biological stability is greatly enhanced by the promotion of bone apposition and increased contact using a roughened titanium surface to the implant. The elimination of the need for membrane technology and guided bone regeneration at the time of surgery, as required around stan-

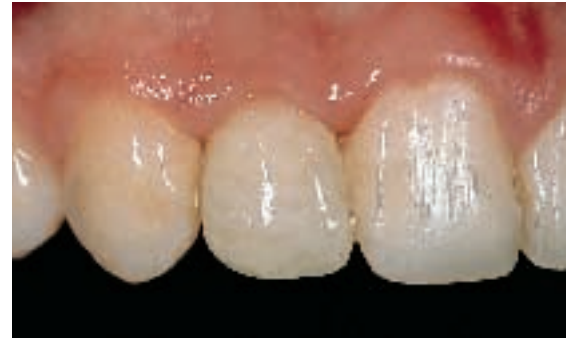

Figure 16—An all-ceramic crown on an aurabase custom abutment is permanently inserted at 7 weeks.

dard diameter cylindrical implant systems, further enhances primary mechanical stability by engaging the surrounding native bone and alleviates the potential complications with recession at the thin soft-tissue interface. In these types of scenarios, the use of the correct armamentarium allows for immediate total tooth replacement (Figures 14 and 15) with placement of the final restoration in 6 to 8 weeks (Figure 16).

References

1. Tarnow DP, Emtiaz S, Classi A: Immediate loading of threaded implants at stage 1 surgery in edentulous arches: Ten consecutive case reports with 1- to 5- year data. *Int J Oral Maxillofac Implants* 12(3):319-324, 1997.
2. Schnitman PA, Wöhrle PS, Rubenstein JE, et al: Ten-year results for Brånemark implants immediately loaded with fixed prostheses at implant placement. *Int J Oral Maxillofac Implants* 2(4):495-503, 1997.
3. Schulte W, Heimke G: The Tübingen immediate implant. *Quintessence* 27(6):17-23, 1976.
4. Wöhrle, PS: Single-tooth replacement in the aesthetic zone with immediate provisionalization: fourteen consecutive case reports. *Pract Periodont Aesthet Dent* 10(9):1107-1114, 1998.
5. Henry P, Rosenberg I: Single-stage surgery for rehabilitation of the edentulous mandible: Preliminary results. *Pract Periodont Aesthet Dent* 6(9):15-22, 1994.
6. Tarnow DP, Magner AW, Fletcher P: The effect of distance from the contact point to the crest of bone on the presence or absence of the interproximal dental papilla. *J Periodontol* 63(12):995-996, 1992.
7. Kois J: Altering gingival levels: the restorative connection. Part I. Biologic variables. *J Esthet Dent* 6:3-9, 1994.
8. Meredith N, Alleyne D, Cawley P: Quantitative determination of the stability of the implant-tissue interface using resonance frequency analysis. *Clin Oral Implant Research* 7:261-267, 1996.
9. Schärer P, Glauser R: Immediate and early loading of implants. Available at: <http://www.worlddent.com/current.issue/articles/scharer.xml>.
10. Garber DA, Salama MA, Salama H: A Solution to Immediate Implant Placement in the External Root Resorption Case. Available at: <http://www.worlddent.com/current.issue/articles/garber.xml>.
11. Johansson P, Strid KG: Assessment of bone quality from cutting resistance during implant surgery. *Int J Oral Maxillofac Implants* 9:279-288, 1994.